

Placenta percreta – a near miss

Gundewar T¹, Kale Y², Ghike S³, Gundewar S⁴

Abstract:

A type of morbidly adherent placenta in which chorionic villi completely invade the myometrium and may invade the serosa or adjoining organs, is known as Placenta Percreta. It is a very rare pregnancy problem and is associated with a high maternal and fetal morbidity and mortality. We present a case of placenta praevia percreta with massive intra-partum hemorrhage requiring an emergency cesarean hysterectomy.

Keywords: Morbidly adherent Placenta, Placenta Percreta, Cesarean Hysterectomy.

¹Junior Resident III,
²Lecturer, ³Professor,
Department of Obstetrics &
Gynecology, NKP Salve
Institute of Medical Sciences
& Research Centre, Dighodh
Hills, Hingna, Nagpur, India
⁴Intern, Government Medical
College, Nagpur
tejasgundewar87@gmail.com

Introduction:

Placenta Accreta is a collective term used to describe all 3 grades of morbidly adherent placenta(1). Depending on histopathology it is graded as follows; Accreta – Chorionic villi attach to myometrium, rather than being restricted to decidua basalis. Increta – Chorionic villi invade into myometrium. Percreta – Chorionic villi through the myometrium and may invade the serosa or adjoining organs.

At present, the incidence of placenta accreta is around 3 per 1000 deliveries. It has been increasing steadily since 1970 & parallels that of the increasing cesarean delivery rate (2-3). Morbidly adherent placenta is the most common cause of a peripartum hysterectomy. It is associated with serious medical and surgical complications (4-5) resulting in approximately 7 percent maternal mortality and a morbidity as high as 60 percent. These patients also have a high perinatal mortality and morbidity, with preterm birth being the prime contributing factor (6-9). Morbidly adherent placenta becomes problematic when placenta does not separate on its own or even after manipulation, resulting in massive obstetric hemorrhage (average 3-5 liters) and its sequel; usually requiring aggressive transfusion of blood products and an emergency cesarean hysterectomy. This exposes the patient to dilutional coagulopathy as well as surgical injury involving the bladder and ureters (10). Almost 90 percent of these patients require blood transfusion, with 40 percent requiring more than 10 units of packed red cells. We present a case of placenta praevia percreta diagnosed on ultrasound with massive intrapartum hemorrhage requiring cesarean hysterectomy.

Case Report:

A 30 year old female, resident of Saran, Bihar, third gravid with one living issue at 36weeks and 6days of gestation with a previous scar presented to the

antenatal outpatient department with complaints of abdominal pain since 7 days. The abdominal pain was dull aching and did not increase in intensity. It was not associated with show, leaking or bleeding per vaginam, burning micturition. She perceived fetal movements well. She had delivered vaginally a female child 11 years back. After that she had a cesarean section 5 years back. Indication of the previous cesarean section was not known as no data was available.

In the present pregnancy she followed up with a private practitioner in a village in Bihar. She had a 5 months sonography report revealing a low lying placenta. There was no significant past surgical or medical history. General examination revealed mild pallor. Systemic examination was insignificant. On abdominal examination the uterus was term size, fetus in cephalic presentation with an unengaged fetal head. Fetal heart sounds were regular. There was no scar tenderness. On per speculum examination the cervix & vagina appeared healthy. There was no bleeding. Per vaginal examination was avoided as the only antenatal scan the patient had, mentioned a low lying placenta. Thus a clinical diagnosis of previous cesarean scar with placenta previa was made. On admission it was found that her routine antenatal investigations were normal except for hemoglobin which was 8.7gm%. Admission test (NST) was reactive. Doppler ultrasound showed a central placenta previa (type IV); loss of interface between retroplacental & myometrial surface, with increased vascularity in the periphery & prominent venous lakes in placenta. Thus, a final diagnosis of a previous cesarean scar with placenta previa accreta was made. Informed written consent regarding need for blood transfusion, cesarean hysterectomy and intensive care unit (ICU) admission was taken; patient was posted for an elective cesarean section. 2 units of whole blood were issued. Under general anesthesia the abdomen was opened with a midline

vertical incision. Bladder was advanced that is it was above the level of isthmus. Prominent venous plexuses in the lower uterine segment were present. Placenta could be seen through visceral peritoneum (Figure 1). Visceral peritoneum was opened; placental separation occurred with torrential bleeding. A female baby weighing 3.36kg was born. Part of the placenta separated on its own. A large chunk was adherent to the lower uterine segment. Torrential bleeding continued even after the use of uterotonics. Decision for a cesarean hysterectomy was taken. 2 more units of whole blood were issued & total abdominal hysterectomy was undertaken. Approximate blood loss during surgery was 3 liters (Figure 2). Post operatively, patient was kept in the obstetric ICU for 48 hours and was discharged on day 10 after suture removal.

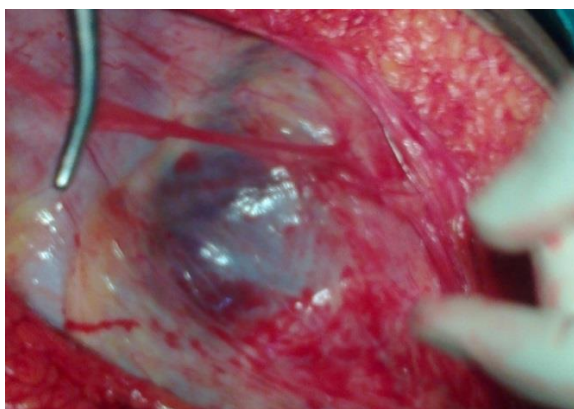


Fig. 1: Placenta seen through visceral peritoneum



Fig. 2: Total blood loss during surgery

Discussion:

Placenta Accreta is a collective term used to describe all 3 grades of morbidly adherent placenta ⁽¹⁾. Depending on the histopathology it is graded as follows;

Accreta – Chorionic villi attach to myometrium rather than being restricted to decidua basalis.

Increta – Chorionic Villi invade into myometrium.

Percreta – Chorionic Villi through the myometrium & may invade the serosa or adjoining organs.

The reported incidence of placenta accreta in 2002 was 1 in 533 deliveries contrasting with an incidence of 1/ 2510 in 1995, 1/7000 in 1970. Wadhwa et al (11) conducted a retrospective study and reviewed the data of patients with clinical diagnosis of morbidly adherent placenta. There was an increase in the incidence every year. Increased rate of caesarean section has been the reason for increasing rate of placenta accreta. They concluded that in patients with previous history of a cesarean section, irrespective of the position of placenta, possibility of a morbidly adherent placenta should be kept in mind. Placenta accreta is the commonest variety of morbidly adherent placenta accounting for almost 70% to 80% of cases, while placenta increta & percreta is seen in 17% & 5% cases respectively. Three-fourth of the cases of placenta percreta are associated with placenta praevia. Grand multiparity, previous caesarean section, history of uterine curettage & previously treated Asherman syndrome are some of the other important risk factors (3). Clark et al performed a study to find the risk of placenta accreta in patients with previous caesarean section & in those with previous caesarean section associated with placenta praevia. They found that the risk of placenta accreta increased with every repeat caesarean section; after the first, second & third caesarean sections, the risk was 0.03, 0.2 & 0.1 percent respectively. In the presence of placenta praevia the risk increased further; it was 3, 11 & 40 percent after 1st, 2nd & 3rd repeat caesarean section respectively.

Ultrasonography (grey scale & colour doppler) & Magnetic Resonance Imaging (MRI) are the available modalities for diagnosis of morbidly adherent placenta. Transvaginal ultrasound is more accurate than abdominal ultrasound for placental localization. A suspected diagnosis of low lying placenta at 20 weeks of gestation by abdominal scan should be confirmed by trans-vaginal ultrasound. According to RCOG (Royal College of Obstetrics & Gynaecology) (12) routine USG at 20 weeks of gestation should include placental localization & those with a low lying placenta (defined as placental edge within 3cm's of internal os) should have a regular follow up imaging. Loss or interruption of retro-placental hypo echoic zone, thinning of the hyper echoic border between bladder & uterine serosa, presence of echogenic masses invading bladder and abnormal placental lacunae (moth eaten or swiss cheese appearance) are ultrasound findings suggestive of placenta accreta. Color Doppler shows hypervascularity of uterine serosa-bladder interface & vascular lakes with turbulent flow(8). Comstock CH et al(13) conducted a study on diagnosis of morbidly adherent placenta in 2005 & concluded that grey scale ultrasonography is sufficient to diagnose placenta accreta; even though best results are

observed with a 3D power color doppler it doesn't increase the sensitivity compared to grey scale ultrasonography. Grey scale ultrasonography has a specificity as high as 96 to 98 percent, sensitivity of 77 to 87 percent, positive predictive value of 67 to 93 percent and negative predictive value of 98 percent for diagnosis of placenta accreta (13).

Role of MRI in morbidly adherent placenta is not well understood. Heterogeneous signal intensity within placenta, dark intraplacental bands & uterine bulging on T2 weighted imaging are findings suggestive of this condition. An MRI doesn't increase the diagnostic accuracy according to most studies. Thus, MRI is usually recommended in cases where an ultrasound is inconclusive.

Management involves a multidisciplinary approach. Proper counselling of the patient along with the relatives and written informed consent about the mode of treatment, risks & complications involved should be taken. An experienced obstetrician, senior anaesthetist, pediatrician, blood & blood products for transfusion, intensive care unit or high dependency unit for postoperative care should be available. Nighat Sultana et al (14) conducted a study in diagnosed cases of placenta accreta to analyse management options and maternal outcome. They concluded that antenatal diagnosis, planned caesarean total hysterectomy without attempting placental separation is the best surgical approach to reduce maternal morbidity & mortality. In a similar study Fitzpatrick KE, Sellers et al (15) observed that if placental separation was not attempted with the aim of either conserving the uterus or prior to caesarean hysterectomy, it was associated with a statistically significantly lowered blood loss and thus this practice was recommended.

In cases where uterine conservation is required management options include leaving the placenta in situ along with the use of methotrexate postoperatively & interventional radiology. In July 2012 ACOG (American College of Obstetrics & Gynaecology) recommended methotrexate as an adjunctive therapy in cases of placenta accreta (16). Methotrexate acts on dividing cells; after delivery trophoblasts no longer divide which renders methotrexate ineffective. Many studies have been performed to evaluate the effectiveness of methotrexate in cases of morbidly adherent placenta and it has yielded mixed results. In one study uterine conservation was achieved but most of these patients developed postpartum hemorrhage requiring emergency peripartum hysterectomy. So, at present there is no conclusive evidence for the use of methotrexate in postpartum management of placenta accreta.

Interventional radiology includes pre-operative catheter placement in the internal iliac artery with post-delivery inflation of these catheter balloons to achieve temporary hemostasis and uterine artery embolization (16). If these management modalities are available, it can be lifesaving in cases of massive postpartum hemorrhage. There are distinct advantages of this approach like preservation of fertility (since it avoids hysterectomy), less blood loss hence decreased need for blood transfusion and its related complications, finally a lower incidence of post procedure complications like fever. At the same time, there are unique problems encountered with this approach like iliac artery thrombosis, uterine artery necrosis, sepsis & at times multiple organ dysfunction syndrome. Rao et al (16) in 2006-2007 described three cases of antenatally diagnosed placenta accreta where interventional radiology was successfully used in the management and led to a favorable outcome for mother and baby. But, currently there is insufficient data to recommend this approach routinely.

Patients of morbidly adherent placenta are prone for many medical and surgical complications. Medical complications include DIC, Sepsis, ARDS, MODS (multiple organ dysfunction syndrome) transfusion related problems viz febrile morbidity, transfusion related acute lung injury, hemolytic transfusion reactions etc. According to ACOG, average blood loss in patients of placenta accreta is 3 to 5 liters. 90 percent of these patients require transfusion of blood & blood products while 40 percent of these require more than 10 units of packed red blood cells. Currently RCOG & ACOG recommend transfusion of 1 FFP (fresh frozen plasma) per one transfused packed red cell unit.

Because of the disturbed pelvic anatomy & frequent need for caesarean total hysterectomy, these cases are more prone for surgical injuries involving the urinary bladder, ureters & thus its sequel like ureteral strictures, urinary stasis, renal & pelvis abscesses.

In general, the recommended management of suspected placenta accreta is an elective caesarean hysterectomy at 36 weeks of gestation without attempting placental separation since attempts to separate it are associated with significant hemorrhagic morbidity. Surgical planning regarding incision site & avoiding incising the placenta should be done. Internal iliac artery ligation or uterine artery embolization can be done to minimize blood loss.

Conclusion:

As caesarean delivery rates rise, so will the incidence of placenta previa thus of morbidly adherent

placenta. Every clinician doing cesarean deliveries must realize the increased risks associated with the next pregnancy and be sufficiently skilled to deal with these complications, which can be formidable. Placenta percreta is a rare disease with a difficult initial diagnosis. Early antenatal diagnosis is a key in optimizing the treatment & outcome in these cases. A planned cesarean hysterectomy with placenta left in situ is probably the preferred treatment. Methotrexate chemotherapy and use of Interventional radiology, remain a viable option, especially in those who wish to conserve fertility; although their effectiveness has not been proven in cases of placenta percreta. Thus a skilled, vigilant, thoughtful obstetrician can go a long way in optimizing the mode of treatment and helping those with morbidly adherent placenta.

References:

1. Hughes EC, editor. Obstetric- Gynecologic terminology with section on neonatology & glossary on congenital anomalies Philadelphia (PA) F.A.Davis, 1972.
2. Read JA, Cotton DB, Miller FC. Placenta Accreta: Changing clinical aspects & outcome. *Obstet Gynecol* 1980;56:31-4.
3. Miller DA, Chollet JA, Goodwin TM. Clinical risk factors for placenta praevia – placenta accrete. *Am J Obstet Gynecol* 1997;177:210-4.
4. R. Faranesh, R. Shabtai, S. Eliezer, and S. Raed, "Suggested approach for management of placenta percreta invading the urinary bladder," *Obstetrics and Gynecology* 2007; vol.110,no.2,pp. 512–515.
5. G. Daskalakis, E. Anastasakis, N. Papantoniou, S. Mesogitis, M. Theodora, and A. Antsaklis, "Emergency obstetric hys- terectomy," *Acta Obstetricia et Gynecologica Scandinavica* 2007; vol. 86, no. 2, pp. 223–227,
6. Hudson L, Belfort MA, Broome DR. Diagnosis and management of placenta percreta: a review. *Obstetrical and Gynecological Survey* 1998; 53(8): 509–517
7. O'Brien JM, Barton JR, Donaldson ES. The management of placenta percreta: conservative and operative strategies. *American Journal of Obstetrics and Gynecology*; 1996 :175(6): 1632–1638.
8. Sumigama S, Itakura A, Ota T. Placenta previa increta/percreta in Japan: a retrospective study of ultrasound findings, management and clinical course. *Journal of Obstetrics and Gynaecology Research* 2007; 33 (5): 606–611..
9. Eller AG, Porter TT, Soisson P, Silver RM. Optimal management strategies for placenta accreta. *An International Journal of Obstetrics and Gynaecology* 2009; 116(5) :648– 654.
10. Hudon L. Diagnosis & management of placenta percreta: a review. *Obstet Gynecol* 1998;53:509-17.
11. Wadhwa L, Gupta S, Gupta P. Morbidly Adherent Placenta (MAP): Lessons learnt. *Open Journal of Obstetrics and Gynecology* 2013; 3: 217-221.
12. RCOG Green-top guidelines No 27, December 2011. www.rcog.org.
13. Comstock CH. Antenatal diagnosis of placenta accreta: a review. *Ultrasound Obstet Gynecol* 2005; 26: 89-96.
14. Nighat Sultana, Sobia Mohyuddin, Tahira Jabbar. Management and maternal outcome in morbidly adherent placenta. *J Ayub Med Coll Abbottabad* 2011; 23(2): 14-18.
15. Fitzpatrick KE, Sellers S, Spark P, Kurinczuk JJ, Brocklehurst P, Knight M. The management and outcomes of placenta accreta, increta, and percreta in the UK: a population-based descriptive study. *BJOG*. 2014 Jan;121(1):62-70;
16. Rao AP, Bojahr H, Beski S, MacCallum PK, Renfrew I. Role of interventional radiology in the management of morbidly adherent placenta *J Obstet Gynaecol*. 2010;30(7):687-9.